

# Pruritic Urticarial Plaques and Tense Bullae During a Second Trimester Pregnancy

---

 [consultant360.com/whats-your-diagnosis/pruritic-urticarial-plaques-and-tense-bullae-during-second-trimester-pregnancy](https://consultant360.com/whats-your-diagnosis/pruritic-urticarial-plaques-and-tense-bullae-during-second-trimester-pregnancy)

Elen Deng, BS , Jill Stachowski, BS , Marc Schlessel, MD , Thomas N. Helm, MD

What's Your Diagnosis?

[Elen Deng, BS,](#)

[Jill Stachowski, BS,](#)

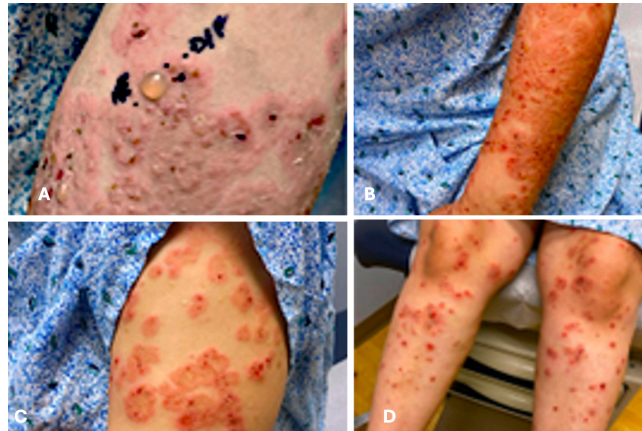[Marc Schlessel, MD,](#)

[Thomas N. Helm, MD](#)

[Volume 65 - Issue 7 - July 2025](#)

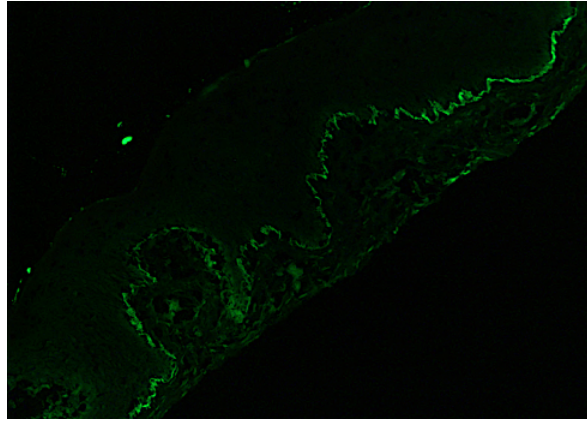
**Introduction.** A 34-year-old woman at 24 weeks gestation presented to the dermatology clinic with a 1-month history of worsening, painful, and pruritic skin eruption.

**History.** The patient's history was remarkable for biopsy-confirmed dermatitis during the third trimester of a prior pregnancy. Direct immunofluorescence (DIF) at that time was non-contributory. Because her dermatitis had not completely resolved postpartum, she was placed on dupilumab 300 mg every other week. Because of persistent pruritus of the hands and feet, she was placed on tralokinumab 300 mg injections every other week for 3 months. She was asymptomatic prior to her current presentation. On physical examination, widespread urticarial plaques progressing to tense bullae were noted on the arms (**Figs. 1-3**) and legs (**Fig. 4**). The eruption extended over her trunk. The remainder of her physical examination was unremarkable.

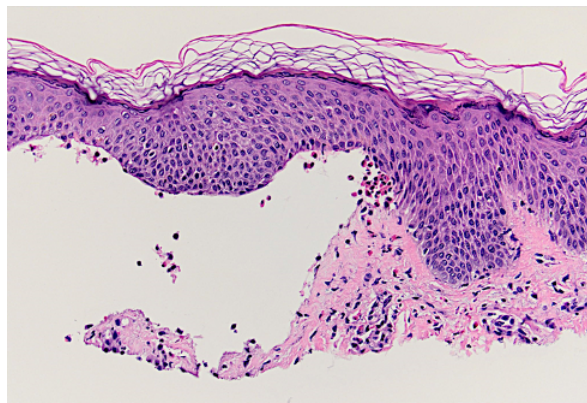


**Figure 1A-D.** Widespread urticarial plaques with tense bullae over the patient's arms and legs are shown.

**Diagnostic Testing.** Two shave biopsies were performed: Left arm medial biopsy for hematoxylin and eosin staining and left arm lateral biopsy for perilesional DIF analysis. (**Figures 2-3**)



**Figure 2.** *DIF reveals linear deposition of C3. IgA and IgG fail to reveal significant staining.*



**Figure 3.** *Hematoxylin and eosin–staining (original magnification ×200) revealed subepithelial blister formation with numerous eosinophils noted within the blister cavity.*

(Answer and discussion on next page)

© 2025 HMP Global. All Rights Reserved.

[Cookie Policy](#) [Privacy Policy](#) [Term of Use](#)

Tray "User-defined shortcuts" opened.

## **Answer: A. Pemphigoid gestationis**

This patient's presentation of urticarial plaques progressing to tense bullae during pregnancy, along with C3 deposition on DIF and eosinophils in the blister fluid, aligns closest to the diagnosis of pemphigoid gestations. Neither atopic eruption of pregnancy nor polymorphic eruption of pregnancy typically present with bullae formation nor demonstrate linear deposition of C3 on DIF microscopy.<sup>1</sup> Bullous pemphigoid shares similar clinical and histopathological features with pemphigoid gestationis, like tense bullae, eosinophilic infiltration, and C3 deposition, but typically affects the elderly.<sup>1</sup>

**Treatment and Management.** At 24 weeks gestation, the patient was started on a tapered regimen of oral prednisone: 60 mg daily for 7 days, followed by 40 mg daily for 7 days, then 20 mg daily for 7 days, and finally 10 mg daily for 7 days. Additionally, the patient was prescribed clobetasol 0.05% ointment to be applied twice daily as needed. The patient was advised to inform her obstetrician of her diagnosis at her forthcoming appointment.

**Outcome and follow-up.** During her 4-week follow-up, the patient's rash recurred with a reduction in prednisone dosage; therefore, the prednisone dosage was maintained at 40 mg daily until her next appointment in 1 month. The patient was also using mupirocin 2% ointment given the concern for impetiginization. At 32 weeks' gestation, the patient's rash was controlled with the continued use of 40 mg prednisone daily. The patient opted against a referral to a high-risk pregnancy specialist due to logistical concerns but is maintaining follow-up with her local obstetrician.

The patient delivered at 38 weeks' gestation and, at 6 weeks postpartum, reported that both she and her newborn son were doing well with clearance of the rash. However, she developed paronychia without abscess formation on the left fourth finger, likely secondary to chronic systemic steroid use. The patient is not currently breastfeeding. At 10 weeks postpartum, the patient experienced a flare following a prednisone taper from 40 mg to 30 mg, which was initiated at her last visit. She also reported a history of gestational diabetes mellitus and possible weight gain attributed to the prednisone. Blood glucose levels will be monitored periodically while the patient remains on prednisone. At this time, the patient was placed back on prednisone 40 mg daily.

At the most recent visit, 14 weeks postpartum, a gradual tapering plan was initiated, starting with 40 mg daily for 7 days, followed by a 5 mg reduction per week. Additionally, the patient was administered a single dose of dupilumab 600 mg, with subsequent biweekly 300 mg injections for concomitant management of atopic dermatitis. Triamcinolone 0.1% ointment was also prescribed to use on itchy rashes as needed. The patient is scheduled for a follow-up appointment in 2 months or earlier if necessary.

**Discussion.** Pemphigoid gestationis, also known as gestational pemphigoid is a rare autoimmune skin disorder that primarily manifests during the second and third trimester of pregnancy but can occur at any point of pregnancy or postpartum<sup>1</sup>. Pemphigoid gestationis' clinical features typically include intense itching on the abdomen, umbilicus, and extremities followed by red papules and urticarial plaques, eventually progressing to blistering. Facial and mucosal lesions are uncommon but may occur in severe cases.<sup>1</sup> The linear deposition of C3 on DIF microscopy is also a supportive finding in pemphigoid gestationis as well as the histopathological results of subepithelial blister formation and eosinophilic infiltration<sup>1</sup>. The pathophysiology of pemphigoid gestationis remains largely unknown, but it is believed to involve an autoimmune reaction against the BP180 and BP230 molecules, which are structural proteins found in both the skin and placental tissues.<sup>2</sup> The clinical symptoms, histological findings, immunofluorescence, and enzyme-linked immunosorbent assay support the diagnosis of pemphigoid gestationis. Linear accumulation of complement C3 in the basement membrane zone on DIF examination is a characteristic finding.<sup>1,3</sup> Treatment options include topical corticosteroids for mild cases and systemic corticosteroids for severe manifestations, with other interventions like plasmapheresis and immunoadsorption reserved for refractory cases.<sup>1</sup>

Pemphigoid gestationis pregnancies carry increased risks of preterm birth and fetal growth restriction with the possibility of transient newborn skin blistering; however, it does not increase the risk of stillbirth or miscarriage.<sup>1</sup> Pemphigoid gestationis symptoms typically resolve within 1 to 2 months post-delivery but may also persist or worsen due to increased antibody levels. Pemphigoid gestationis may also recur in future pregnancies or with hormonal changes, necessitating ongoing monitoring, especially postpartum and during menstruation or hormonal contraceptive use.<sup>1,4</sup> While this case provides information on the short-term management and outcome of pemphigoid gestationis, it lacks detailed long-term follow-up data beyond the immediate postpartum period which would provide insights into the long-term resolution of symptoms and potential recurrence in future pregnancies.

Atopic eruption of pregnancy (AEP) and polymorphic eruption of pregnancy (PEP) are other common differential diagnoses for pregnancy-associated pruritic dermatoses. AEP typically presents with pruritic eczematous lesions commonly on the trunk and extensors of the extremities and IgE levels may be elevated on serology<sup>1</sup>. PEP, on the other hand, presents with pruritic urticarial papules and plaques, often sparing the umbilical region, and does not typically progress to bullae formation<sup>1</sup>. Additionally, neither AEP nor PEP typically demonstrate linear deposition of C3 on DIF microscopy, as seen in pemphigoid gestationis.<sup>1</sup>

Bullous pemphigoid is a subepidermal autoimmune blistering disorder that shares some clinical features with pemphigoid gestationis, such as tense bullae formation. Histopathological examination of bullous pemphigoid typically reveals subepidermal split with eosinophilic infiltration and DIF usually shows a linear deposition of C3 and IgG at the

basement membrane, similar to pemphigoid gestationis.<sup>5</sup> However, bullous pemphigoid typically occurs in elderly individuals while pemphigoid gestationis characteristically occurs during pregnancy or in the postpartum period.<sup>1,5</sup>

**Conclusion.** This case highlights the importance of considering pemphigoid gestationis as a differential diagnosis in a pregnant patient with clinical features of widespread urticarial plaques and tense bullae, especially during the second and third trimesters of pregnancy. Prompt diagnosis and treatment with initiation of oral prednisone taper can help control symptoms and minimize potential complications for both the mother and fetus. Additionally, close follow-up and monitoring are necessary to address any potential relapses and ensure optimal maternal and fetal outcomes.

**AUTHORS:**

Elen Deng, BS<sup>1</sup> Jill Stachowski, BS<sup>1</sup>, Marc Schlessel, MD<sup>2</sup>, Thomas N. Helm, MD<sup>2</sup>

**AFFILIATIONS:**

<sup>1</sup>Penn State College of Medicine, 700 HMC Crescent Road, Hershey, PA 17033

<sup>2</sup>Penn State Health, Department of Dermatology, Hershey, Pennsylvania 17033

**CITATION:**

Deng E, Stachowski J, Schlessel M, Helm TN. Pruritic urticarial plaques and tense bullae during a second trimester pregnancy. *Consultant*. Published online March 4, 2025. doi: 10.25270/con.2025.03.000006

Received September 23, 2024. Accepted October 28, 2024.

**DISCLOSURES:**

The authors report no relevant financial relationships.

**ACKNOWLEDGEMENTS:**

None.

**CORRESPONDENCE:**

Elen Deng, BS, 1850 E Park Ave, State College, PA 16803  
(edeng@pennstatehealth.psu.edu)

**References**

1. Huilaja L, Mäkikallio K, Tasanen K. Gestational pemphigoid. *Orphanet J Rare Dis*. 2014;9:136. doi:10.1186/s13023-014-0136-2
2. Daniel BS, Murrell DF. Review of autoimmune blistering diseases: the Pemphigoid diseases. *J Eur Acad Dermatol Venereol*. 2019;33(9):1685-1694. doi:10.1111/jdv.15679

3. Jiao HN, Ruan YP, Liu Y, Pan M, Zhong HP. Diagnosis, fetal risk and treatment of pemphigoid gestationis in pregnancy: A case report. *World J Clin Cases*. 2021;9(34):10645-10651. doi:10.12998/wjcc.v9.i34.10645
4. Stefaniak AA, Pereira MP, Zeidler C, Ständer S. Pruritus in Pregnancy. *Am J Clin Dermatol*. 2022;23(2):231-246. doi:10.1007/s40257-021-00668-7
5. Baigrie D, Nookala V. Bullous Pemphigoid. Bullous Pemphigoid. StatPearls. Updated March 2, 2023. Accessed May 29, 2024.  
<https://www.ncbi.nlm.nih.gov/books/NBK535374/>

©2025 HMP Global. All Rights Reserved.

***Any views and opinions expressed are those of the author(s) and/or participants and do not necessarily reflect the views, policy, or position of Consultant360 or HMP Global, their employees, and affiliates.***